

Detection of Human papillomavirus 16 and 18 types in oral squamous cell carcinoma patients in Yazd, Iran :A Case-Control Study

Seyyed Hossein Tabatabai¹, Minoos Nabieyan^{1*}, Mohammad Hasan Sheikhha², Shokouh Taghi Poor zahir¹, Sedigheh Zarmehi¹, Azadeh Andisheh Tadbir³, Nayeb Ali Ahmadi⁴

¹Department of clinical and surgical pathology, Shahid Sadoughi University of Medical Sciences, Yazd, Iran

²Genetics Department, Research and Clinical Center for Infertility, Shahid Sadoughi Medical Sciences University, Yazd, Iran.

³Department of Oral and Maxillofacial Pathology, School of Dentistry, Shiraz University of Medical Sciences, Shiraz, Iran

⁴Proteomics Research Center, Department of Medical Laboratory Technology, Faculty of Paramedical Sciences, Shahid Beheshti University of Medical Sciences, Tehran, Iran

*Corresponding Author: email address: minoos6836@gmail.com (M. Nabieian)

ABSTRACT

The aim of this study was to ascertain the prevalence of human papillomavirus (HPV) 16/18 in oral squamous cell carcinoma (OSCC) and normal oral mucosa in Iranian individuals with OSCC and their association with various risk factors. The investigation followed a hospital-based case-control design. Cases were individuals with diagnosed OSCC, age- and sex-matched with controls. Sixty-six paraffin embedded tissue samples (39 OSCC and 27 normal oral mucosa) were studied. DNA was purified to amplify HPV-DNA using HPV type specific primers-mediated polymerase chain reaction (PCR) method. Mean age was 64.2 ± 14 years in cases (range 25-81 years), and 63.5 ± 13.5 years in controls (range 22-78 years). Forty-three percent (17/39) of OSCC but none of normal oral mucosa were positive for HPV 16/18 DNA ($p = 0.001$). The most frequent type in patient group was HPV-16 type. The prevalence rate was high older in age (>50 years) and gender (male) and tongue tissue but no significant association was found ($p=0.7$, $p=0.5$ and $p=0.42$ respectively). We found a significant association of HPV16/18 with oral squamous cell carcinoma. Also, HPV16/18 is a co-factor in oral carcinogenesis. In addition, also it is suggested that HPV is as a risk factor independent of alcohol and tobacco can be effective in creating OSCC.

Key words: human papillomavirus 16 and 18 types; oral squamous cell carcinoma; PCR

INTRODUCTION

Squamous cell carcinoma (SCC) is the most common malignant neoplasm of the oral mucosa, representing more than 90% of these malignant tumors. This most common malignancy includes a multifactorial disease that recently the tobacco and alcohol has been considered as the causes main factors [1, 2].

As study of Elango and et al, probably due to the habits reduction in high-risk countries, there is an overall reduction in the incidence of head and neck cancers especially as laryngeal carcinoma and buccal-gum carcinoma that associate with abuse of tobacco in both urban and rural communities [3]. Despite general decrease in the incidence of head and neck cancers, but its increased incidence in

certain regions such as oropharynx [4] tongue [3] and oral cancers in the younger adults has been observed [5].

In the last decade, oral cancer institute of America (OCIOA) has announced that OSCC rate has decreased in men than women because women increasingly are smoking and alcohol. However, in a study of Yazd city (southern of Iran) in 2011, showed no significant difference in incidence between men and women, while tobacco and its products according to the cultural and social conditions of the population, was significantly in women fewer than men [6]. In generally, OSCC rate has increase in patients based on specific tissue such as mouth and tongue [3] and the oropharynx [4] and also among women without

other unknown etiologic factors which the presence of other etiological factors was raised.

Over the past three decades, information support that the human papilloma virus (HPV) is as a causative factor in the development and progression of head and neck cancers, particularly those that originate from the oropharynx [7]. A study in America suggested that HPV such as tobacco and alcohol is as cause of many oral cancers [8]. It seems that persistent infection by HPV might increase the risk of SCC [9]. HPV is a large group of viruses DNA in which more than 100 types has already been identified. Based on the clinical behavior of HPV infections the viruses can be grouped into high risk and low risk HPV types that at least 24 species have been associated with head and neck lesions [1]. A subgroup of HPVs such as high-risk HPVs (HR-HPVs) including types 16, 18, is closely associated with cervical cancer that have a propensity to undergo carcinogenesis [9] that HPV-16 is the most common type seen in OSCC of head and neck [10]. The overall incidence of HPV varies with geographic regions that depending on the tumor location and the techniques used in the detection of viruses. HPV is detected by in situ hybridization (ISH), immunohistologic report analytical chemistry (IHC) and polymerase chain reaction (PCR) techniques [1]. Evaluation of HPV in tumor tissues performed mainly based on the detection of viral DNA by ISH and PCR methods [11]. In most studies has been used PCR method than ISH [12] and is currently the most sensitive method for HPV-DNA detection [13].

In order to prove the hypothesis that the etiologic role of HPV in OSCC is created or that its presence in these lesions is only incidental findings therefore researchers designed to case-control study in first time in Iran.

PATIENTS AND METHODS

In this study, firstly, to control confounding variables, samples from patients diagnosed with OSCC in the region of Iranian population (Yazd city) although yet unknown etiologic factors may still exist, there is the possibility to eliminate them. The study was conducted on the medical documents of patients with head and neck tumors that the histopathological diagnosis of OSCC was

confirmed. This study is a hospital-based case-control design that the collection of information performed from the medical documents. The inclusion criteria for this study were a) availability of sufficient paraffin-embedded tumor material; b) presence of oral cavity cancer (including oral tongue, floor of mouth, gingival, lips, buccal mucosa) [14], c) no previous head and neck cancer; d) no prior oncological therapy; e) histological-proven squamous cell carcinoma, f) and history of tobacco and its products as a habit, at least to the extent of 5 times per week for at least a period of 2 years have not been were investigated by interview. The diagnosis of OSCC was based on histological examination of H&E-stained tissue sections (diagnosis of OSCC was based on histological examination of H&E stain but detection of HPV DNA was by PCR). A total of 39 formalin-fixed paraffin-embedded blocks of patients with histologically proven OSCC cancer and 27 case of normal oral mucosa as normal sample were obtained from archival specimens of Pathology Department, Yazd University of Medical Sciences, Shahid Sadoughi hospital during a 10 years period (2001-2011) were included. These subjects were selected from the same hospital where cases had been recruited, and matched to cases on the basis of gender and age. Second, to assess the etiologic role of HPV control samples used for age, sex and location of the lesion groups were matched but no malignant or benign papillary lesions associated with HPV precancerous and are in the sample.

DNA extraction:

The 10% formalin-fixed and paraffin-embedded tumor specimens were serially sectioned by a microtome. The microtome blade used was disposable and all tools and the surrounding area were cleaned with xylene and ethanol after processing each sample to avoid contamination among samples. The first and last sections were stained with Hematoxylin-Eosin (H&E) to confirm the OSCC diagnosis. Paraffined tissue was dissolved with xylene; Digestion of tissues was done with proteinase K. DNA was purified by DNA extraction according to standard protocols with the Qiagen QIAmp tissue extraction kit (Qiagen, Inc., Santa Clarita, CA). DNA was dissolved in TE buffer (10 mM Tris, 1 mM EDTA,

pH 8.0) and the concentration determined by OD reading at 260 nm. B-globin PCR was used as an internal control for the equal loading of DNA. DNA quality was assessed by amplification of a fragment of the human B-globin gene using PCO3p/PCO4p primers, resulting in a 110 base pairs DNA fragment. Two controls were used for each sample described as negative control (containing DNA purified cultures of HPV-negative cell line Wi38) and positive control (containing DNA purified cultures of Hela cells infected with HPV-18) (15).

Polymerase chain reaction (PCR) Amplification:

All samples positive for b-globin were checked for HPV DNA. The 66 good-quality DNA of cases and control samples use to PCR reaction. For HPV DNA detection was performed according to AmpliSens® HPV 16/18-EPh kit. A final reaction volume of 50µl, containing 5µl of template DNA, 5µl 10X PCR buffer, 4 µl MgCl₂ (50 mM), 1µl dNTPs (100 mM), 5µl of one of the primers (10 mM), and 0.5 µl of Taq DNA Polymerase (5 U/ml).

The PCR conditions were as follows: preheating for 5 min at 94°C was followed by 38 cycles of 1 min at 94°C, 1 min at 55°C and 1 min at 72°C and a final extension of 7 min at 72°C. All the experiments were duplicated. The PCR assays were performed using Gene Amp PCR System 9700 (PE Applied Bio- systems, USA), and the PCR products were analyzed on 2% agarose gels. PCR products size of HPV-16 and 18 is 325bp and 425bp respectively. Of course, size of internal control (IC) is 836bp.(PCR reaction and primers was based on Kit)

RESULTS

Tissue samples were available from 39 cases of OSCC operated between 2001 and 2011. We use from embedded tissues that were gathered during 10 years and control group has been not from patients. After DNA extraction, samples were found suitable for PCR. The other 39 samples (22 males and 17 females) were included in the study as cases. Twenty-seven control subjects (18 males and 9 females), age-matched to cases, were selected from patients who were endoscopies for dyspepsia and had normal endoscopies. Mean ± SD age was 64.20 ±14.8 years in cases (range 25-81 years), and 63.59±13.53 years in controls (range 22-78 years). Topological sections in both groups summarized in Table 1. In both groups the tongue (35.9% and 33.2% respectively) was the most frequent in these tissues followed by floor of the mouth (29.8% and 25.9% respectively). None of the OSSC patients had any tobacco exposure and alcohol consumption that in the control group was similar in both risk factors.

HPV detection and typing:

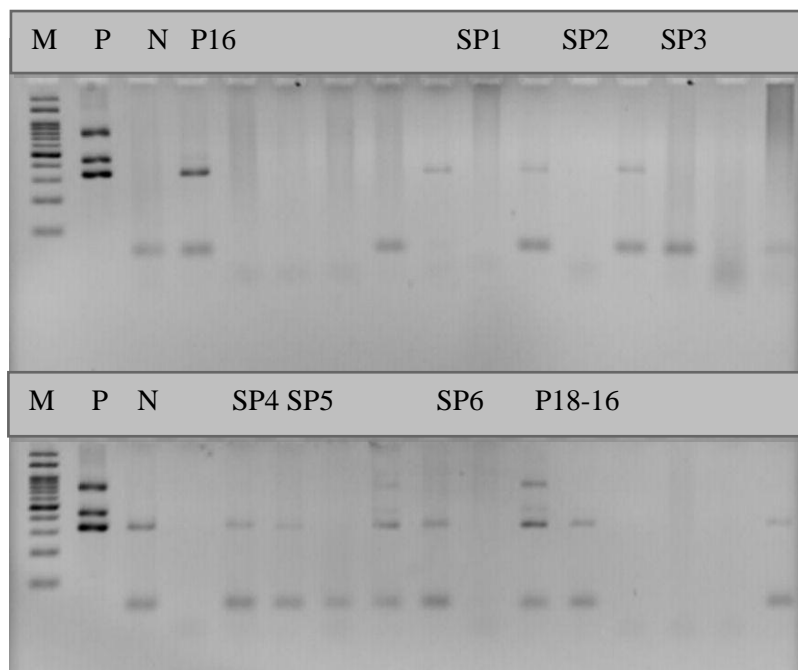
Seventeen (43.6%) of the 39 OSCC samples were positive for HPV-16 DNA but none of the 27 control samples were positive for HPV-16 DNA (P =0.001). Five of the 17 of the OSCC positive samples were positive for HPV-18 DNA but none of the 27 control samples were positive for HPV-18 DNA. Therefore 5 samples were positive for both HPV16 and HPV18. Distribution of HPV-DNA 16 and 18 types based on age, sex, involved site listed in Table 2.the most frequent HPV-16 seen in the patients age higher 50 years (42.8%) but was not statistically significant (P =0.42).

Table 1. Demographic and clinical characteristics OSCC and control patients

Characterize	OSCC group	Control group	P Value
Sex	Female	17(43.6%)	0.86
	Male	22(56.4%)	
Age	>50	25(64.1%)	0.4
	<50	14(35.9%)	
Tissue location	Tongue	14(35.9%)	0.94
	Mouth	4(10.3%)	
	Lip	10(29.8%)	
	Buccal mucosa	7(17.6%)	
	Alveoli	4(10.3%)	

Table 2. Distribution of HPV-16 and HPV-18 based on demographic and clinical characteristics

Frequency of HPV 16&18 variables		Positive samples (%)			Negative samples (%)	Total	P Value
		HPV-16	HPV-16 & 18	Positive total			
Tissue location	Tongue	3 (21.45)	1 (7.1)	4 (28.8)	10 (71.4)	14	0.72
	Aleoul	1 (25)	0	1 (25)	3 (75)	4	
	Buccal	3 (42.8)	0	3 (42.8)	4 (57.2)	7	
	Lip	3 (30)	2 (20)	5 (50)	5 (50)	10	
	Mouth	2 (20)	2 (20)	4 (100)	0	4	
Gender	Male	7 (31.4)	2 (9.9)	9 (40.9)	13 (50.9)	22	0.54
	Female	5 (29.3)	3 (17.6)	8 (52.9)	9 (47.5)	17	
Age	≥ 50	12 (42.8)	3 (10.7)	15 (53.5)	13 (46.5)	28	0.42
	< 50	0	2 (11.9)	2 (11.9)	9 (81.8)	11	
Sample total	All tissues	12 (30.7)	5 (12.8)	17 (43.5)	22 (56.5)	39	

**Figure 1.** HPV 16 and 18-specific primers-mediated PCR of DNA extracted from oral squamous cell carcinomas. PCR products are shown after electrophoresis of 2% agarose gel stained with ethidium bromide. M: marker, P: positive control, N: negative control, P16: HPV-16, P18-18: HPV16-18, SP1-6: positive sample.

The most frequent HPV-16 has been seen tongue tissue than other sites but was not statistically significant ($P=0.72$). In both gender, frequency of HPV-DNA in OSCC patients was not statistically significant ($P=0.54$).

DISCUSSION

Although many studies over the past two decades based on establish the role of HPV in OSCC have been performed but no was in Yazd province of Iran and has been inconsistently reported [16]. The present study is the first case-control study of oral cancer performed in an Iranian population. The results showed a strong association between human papilloma virus infection and oral squamous cell carcinoma. In recent study of HPV detection rates among OSCC patients without risk factors such as alcohol and tobacco, 43.5% (17 out of 39 samples) but none of samples in control group was detected HPV DNA. HPV prevalence in OSCC was in accordance with recent population-based case-control studies [17-19].

In all of these studies, the identification of viral DNA sequences was performed with sets of primers based on HPV sequence and under similar PCR. The most common HPV types detected were HPV-16 which is consistent with the majority of OSCC reports in Iran and other regions [19, 20].

In recent study, prevalence rate of HPV 16 and 18 types in benign lesions was not associated with oral HPV. No DNA-HPV was detected in the control group. This result is similar to this Khademi and Maleki in Iran [21, 22], there was no virus in the saliva of healthy individuals but contrary to the Sahebamei study in Iran [20] and other studies in other regions of world [23, 24] that the DNA-HPV was detected in controls group that rate of detection was varies in these studies. The reason for this discrepancy may be the sampling of tissue for DNA extraction because the amount of sample and the number of cells are low and may lead to false negative results.

Oral cancer is mainly seen in males. In this study detected HPV type 16 in men groups than women that was parallels with the Kreimer study that prevalence of HPV in OSCC men groups

than women or at least is equal [25]. This data was contrast to other study in Iran that prevalence of HPV in OSCC in females is higher than males [26]. Therefore we think cannot definitively state that gender is risk factor on affecting the HPV prevalence in this study and more study's needs.

As we know oral squamous cell carcinoma is a disease that is associated with age and numerous studies have been reported that HPV prevalence was related to the age of the patients. In the present study, although the relation between HPV prevalence and age showed no significant difference but the prevalence of HPV in older people above 50 years was higher than below 50 years. The results of different studies are inconsistent (Kojima, cruze) [27, 28]. In other studies, no significant differences was between HPV positivity rate among elder and young aged people [29] but in other studies, HPV 16 and 18 in OSCC in below of the age of 50 were higher than older than 50 [23]. This finding may be due to differences in sexual behavior.

Oral cancer is more common in tongue than in other tissue. In this study, the most involved tissue in OSCC was the tongue that was similar to other studies in Iran [26]. But in contrast to some other Asian countries which buccal mucosa was the most common site of involvement but in recent study, no statistically significant differences were found that may be because of difference in various habits in previous studies [30].

In conclusion, results of this study have indicated that HR-HPVs were strongly associated with oral cancer in a group of Iranian patients, suggesting that high-risk papilloma virus plays a role in oral carcinogenesis. Although this study, the hypothesis of etiologic role of HPV in the development of OSCC in tongue and in young adults does not confirm but supports that HPV in OSCC creation in some patients is effective, also it is suggested that HPV is as a risk factor independent of alcohol and tobacco can be effective in creating OSCC. In that case, it would be useful to conduct cohort studies on HPV infection in OSCC regions that could allow us to characterize the persistence of HPV in normal and patients.

REFERENCES

1. Lee C-mA, Damm DD, Neville BW, Allen C, Bouquot J. Oral and maxillofacial pathology: Elsevier Health Sciences. 2008;p: 362-452.
2. Regezi JA, Sciubba JJ, Jordan RC. Oral pathology: clinical pathologic correlations: *Health Sciences*; 2012;p:51-78.
3. Elango JK, Gangadharan P, Sumithra S, Kuriakose M. Trends of head and neck cancers in urban and rural India. *Asian Pac J Cancer Prev*. 2006;7(1):108-12.
4. Shiboski CH, Schmidt BL, Jordan RC. Tongue and tonsil carcinoma. *Cancer*. 2005;103(9):1843-9.
5. Macfarlane G, Boyle P, Scully C. Rising mortality from cancer of the tongue in young Scottish males. *Lancet*. 1987;330(8564) ;p:912.
6. Tabatabaei H, Dannesh ardakani M, Shekari A, Rostami F. A Comparative study on Knowledge of General Dentists and Dental Interns about Oral Squamous Cell Carcinoma. *The Journal of Shahid Sadoughi University of Medical Sciences*. 2014;22(1):952-62.
7. Elango KJ, Suresh A, Erode EM, Subhadradevi L, Ravindran HK, Iyer SK, et al. Role of human papilloma virus in oral tongue squamous cell carcinoma. *Asian Pac J Cancer Prev*. 2011;12(4):889-96.
8. Chaturvedi AK, Engels EA, Anderson WF, Gillison ML. Incidence trends for human papillomavirus-related and-unrelated oral squamous cell carcinomas in the United States. *J Clin Oncol*. 2008;26(4):612-9.
9. Rautava J, Syrjänen S. Human papillomavirus infections in the oral mucosa. *J Am Dent Assoc*. 2011;142(8):905-14.
10. of human papillomavirus (HPV) on cancer risk and overall survival in head and neck squamous cell carcinomas (HNSCC). *Head Neck*. 2010;2:1-15.
11. Syrjänen S. The role of human papillomavirus infection in head and neck cancers. *Ann Oncol*. 2010;21(7):243-5.
12. Termine N, Panzarella V, Falaschini S, Russo A, Matranga D, Muzio LL, et al. HPV in oral squamous cell carcinoma vs head and neck squamous cell carcinoma biopsies: a meta-analysis (1988–2007). *Ann Oncol*. 2008;19(10):1681-90.
13. Cantley RL, Gabrielli E, Montebelli F, Cimbaluk D, Gattuso P, Petruzzelli G. Ancillary studies in determining human papillomavirus status of squamous cell carcinoma of the oropharynx: a review. *Patholog Res Int* 2011; 138469 [PMID: 21772959 DOI: 10.4061/2011/138469].
14. McLaughlin JK, Gridley G, Block G, Winn DM, Preston-Martin S, Schoenberg JB, et al. Dietary factors in oral and pharyngeal cancer. *J Natl Cancer Inst*. 1988;80(15):1237-43.
15. Pintos J, Black MJ, Sadeghi N, Ghadirian P, Zeitouni AG, Viscidi RP, et al. Human papillomavirus infection and oral cancer: a case-control study in Montreal, Canada. *Oral onco*. 2008;44(3):242-50.
16. Scully C, Bagan J. Oral squamous cell carcinoma overview. *Oral onco*. 2009;45(4):301-8.
17. B.R. Ibieta ML, M. Frías-Mendivil, J.L. Barrera, A. Carrillo, L. Ma Ruíz-Godoy, et al. Human papilloma virus in oral squamous cell carcinoma in a Mexican population. *Oral Surg Oral Med Oral Pathol Oral Radiol Endod*, 99 (2005), pp. 311–315.
18. Hansson BG, Rosenquist K, Antonsson A, Hansson BG, Rosenquist K, Antonsson A, et al. Strong association between infection with human papillomavirus and oral and oropharyngeal squamous cell carcinoma: a population-based case-control study in southern Sweden. *Acta Otolaryngol*. 2005;125(12):1337-44.
19. Zhao D, Xu Q-g, Chen X-m, Fan M-w. Human papillomavirus as an independent predictor in oral squamous cell cancer. *Int J Oral Sci*. 2009;1(3): 19-25.
20. Delavarian Z, Pakfetrat A, Falaki F, Pazouki M, Pazouki N. The Role of Viruses in Oral Squamous Cell Carcinoma in Young Patients in Khorasan (Northeast of Iran). *J Appl Sci*. 2010;10(11); 981–985.
21. SahebJamee M, Boorghani M, Ghaffari S-R, AtarباشiMoghadam F, Keyhani A. Human papillomavirus in saliva of patients with oral squamous cell carcinoma. *Med Oral Patol Oral Cir Bucal*. 2009;14(10): 525-8.
22. Herrero R, Castellsagué X, Pawlita M, Lissowska J, Kee F, Balaram P, et al. Human

papillomavirus and oral cancer: the International Agency for Research on Cancer multicenter study. *Natl Cancer Inst.* 2003;95(23):1772-83.

23. McKaig RG, Baric RS, Olshan AF. Human papillomavirus and head and neck cancer: epidemiology and molecular biology. *Head neck.* 1998;20(3):250-65.

24. Terai M, Hashimoto K, Yoda K, Sata T. High prevalence of human papillomaviruses in the normal oral cavity of adults. *Oral Microbiol Immunol.* 1999;14(4):201-5.

25. Kreimer AR VA, Nyitray AG, Abrahamsen M, Papenfuss M, Smith D, et al. The epidemiology of oral HPV infection among a multinational sample of healthy men. *Cancer Epidemiol Biomarkers Prev* 2011;20:172–82.

26. Seifi S, Kermani IA, Dolatkah R, Kermani AA, Sakhinia E, Asgarzadeh M, et al. Prevalence of Oral Human Papilloma Virus in Healthy Individuals in East Azerbaijan Province of Iran. *Iran J Public Health.* 2013;42(1):79.

27. Kojima A, Maeda H, Sugita Y, Tanaka S, Kameyama Y. Human papillomavirus type 38 infection in oral squamous cell carcinomas. *Oral onco.* 2002;38(6):591-6.

28. Cruz I, Snijders P, Steenbergen R, Meijer C, Snow G, Walboomers J, et al. Age-dependence of human papillomavirus DNA presence in oral squamous cell carcinomas. *Eur J Cancer B Oral Oncol.* 1996;32(1):55-62.

29. Mork J, Lie AK, Glattre E, Clark S, Hallmans G, Jellum E, et al. Human papillomavirus infection as a risk factor for squamous-cell carcinoma of the head and neck. *N Eur J Cancer B Oral Oncol.* 2001;344(15):1125-31.

30. Andisheh-Tadbir A, Mehrabani D, Heydari ST. Epidemiology of squamous cell carcinoma of the oral cavity in Iran. *J Craniofac Surg.* 2008;19(6):1699-702.